"CELOX (CHITOSAN) IN THE TREATMENT OF TRAUMATIC HAEMORRHAGES: EXPERIENCE IN AFGHANISTAN"

M. Pozza[1] , R.W. Millner [2]
[1] Medical Officer Italian Army, Doctoral Research Candidate Università di Modena e Reggio Emilia
[2] Department of Cardiac Surgery, Blackpool Victoria Hospital, UK
E-mail : mori_8@yahoo.it

INTRODUCTION: On the battle field massive haemorrhage is the primary cause of preventable death. Very often the single gauzes and pressure points are not enough to stop haemorrhaging. The Tactical Combat Casualty Care protocol recommends that each soldier has in his possession a tourniquet and haemostatic agents.

Haemostatic agents have been developed to achieve control of haemorrhages in those areas (neck, groin, armpit etc.) where a tourniquet cannot be applied. These agents can be used to make removing the tourniquet possible when there are long delays in the evacuation of the wounded person.

MATERIALS AND METHODS: Between April and October 2008, in an advanced American medical facility in south-western Afghanistan, 21 soldiers with gunshot wounds were treated with Celox (SAM Medical, Newport, Oregon, USA), a granular chitosan. All the patients were males between the ages of 18 and 45, of Caucasian origin. Of these, 13 presented wounds to the lower limbs, 4 to the upper limbs, 3 to the shoulders and one to the neck. A tourniquet could not be applied to 6 of them because of the anatomical location of the wounds. For the penetrating wounds special applicators of Celox were created using 10 to 20 ml syringes which made it possible to apply the chitosan deep inside the wound.

Fig.1. Exit hole on neck of bullet cal. 7.62 (gun AK 47).

BODY PART	No. of PATIENTS	TOURNIQUET ALREADY APPLIED UPON	LIFE SAVING TREATMENT	OUTCOME
UPPER LIMBS	4	4	3	ALL TRANFERRED TO ROLE 3. NO FEEDBACK
LOWER LIMBS	13	11	9	2 FASCIOTOMY, 11 TRANSFERRED TO ROLE 3. NO FEEEDBACK
SHOULDER	3	0	3	ALL TRANFERRED TO ROLE 3. NO FEEDBACK
NECK	1	0	1	SURGICAL TREATMENT THEN TRANFERRED TO ROLE 3

Tab. 1. Summary of patients treated with Celox.

Fig 2. Exit hole left shoulder from bullet cal 7.62 (AK 47) after application of Celox.

Fig. 3. Application with syringe of Celox in exit hole left shoulder bullet 7.62 (AK 47).

Fig.4. Entry and exit hole after application of Celox.

Fig 5. Formation of coagulum after application of Celox.

Fig.6. Exit hole lower left limb from bullet cal. 7.62 (AK 47).

Fig.7. Exit hole lower left limb after application of Celox.

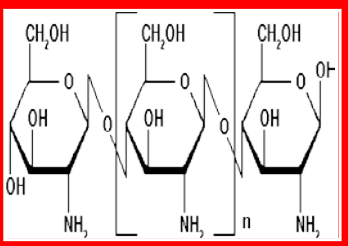

Fig.8. Chemical structure of chitosan, a polysaccharide composed of D-glucosamine e N-acetyl-D-glucosamine.

RESULTS: In 18 patients haemostasis was obtained in less than one minute while for three patients whose arterial haemorrhage was massive further applications were necessary. Once haemostasis had been achieved with the formation of the coagulum, compressive medication was applied. For 15 patients with wounds to the limbs, once haemostasis had been obtained, the tourniquet was removed. In all cases, the haemorrhage was controlled and it was not necessary to reposition the tourniquet. The patients did not suffer pain either during or after the application of Celox and damage to the surrounding tissues did not emerge.

Fig.9. Radiography lower right limb hit by bullet cal. 7.62 (AK 47).

Fig. 10. Exit hole lower right limb after application of Celox.

Tab. 2. Graph of the haemostasis obtained in less than 1 minute in 18 patients and more than 1 minute in 3 patients.

CONCLUSION: This experiment shows that granular Celox has a rapid haemostatic action in producing a stable coagulum. Improvised applicators for penetrating wounds made it possible to achieve an effective haemostasis by pushing chitosan deep into the wound. This haemostatic agent could also be used in national emergency in Italy.

BIBLIOGRAPHY:

Champion HR, Bellamy RF, Roberts CP, et al. A profile of combat injury. J. Trauma. 2003; 54: S13-9.
Butler FK Jr, Holcomb JB, Giebner SD, et al. Tactical combat casualty care 2007: evolving concepts and battlefield experience. Mil.Med. 2007; 172(11 Suppl): 1-19.
Klokkevold PR, Fukayama H, Sung EC, et al. The effect of chitosan (poly-N-acetyl-glucosamine) on lingual hemostasis in heparinized rabbits. J. Oral Maxillofac. Surg. 1999; 57: 49-52.
Kozen BG, Kircher SJ, Henao J, et al. An alternative hemostatic dressing: comparison of Celox , Hemcon, and QuickClot. Acad. Emerg. Med. 2008; 15(1):74-81.
Russell WJ, Alan S, Lockhart AS, et al. A new hemostatic agent: initial life-saving experience with Celox (chitosan) in Cardiothoracic Surgery. Ann.Thorac. Surg. 2009; 87(2): e13-4.